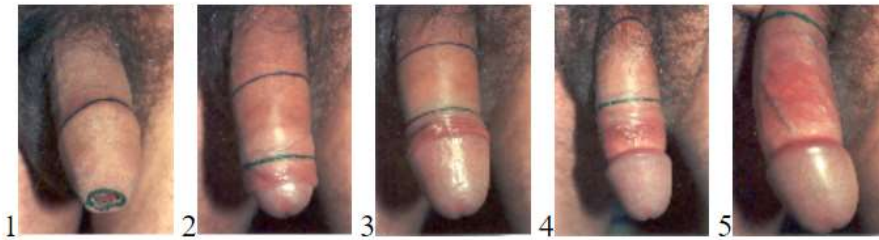


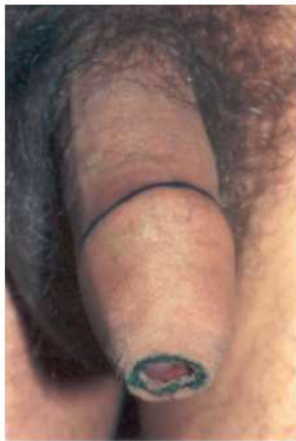The Three Zones of Penile Skin

By John A. Erickson

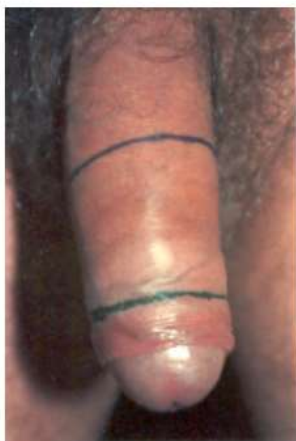

These five photographs show the three zones of skin on a normal, intact (non-circumcised) adult penis:

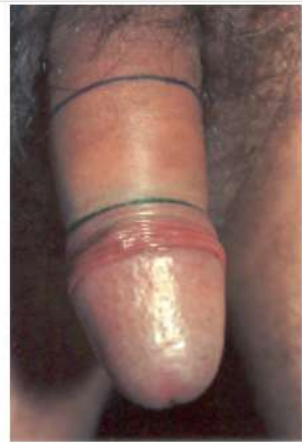- A. the skin covering the shaft (the area above the upper [blue] line in each photograph);
- B. the foreskin's outside fold (the area between the two lines in each photograph);
- C. the foreskin's inside fold (the area below the lower [green] line in each photograph), visible only when the foreskin is retracted.



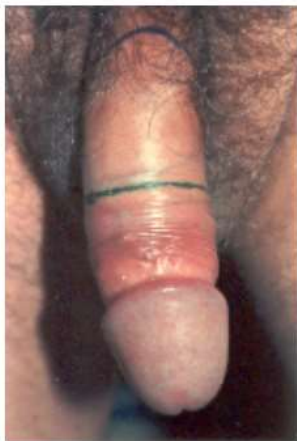1. Penis slightly tumescent. The area between the upper (blue) line and the lower (green) line is the foreskin's outside fold. The foreskin's outside fold is almost as long as the skin covering the shaft. The foreskin's inside fold, equal in length to and covered by the foreskin's outside fold, is not visible. Well over half of the total penile skin is foreskin.



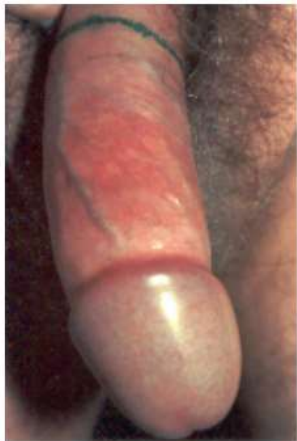2. The foreskin retracted (manually) about an inch. The area between the upper (blue) line and the lower (green) line is the foreskin's mostly retracted outside fold. The area below the lower line is the first half inch or so of the foreskin's partially retracted inside fold.



3. The foreskin retracted. The area between the upper (blue) line and the lower (green) line is the foreskin's retracted outside fold. The area below the lower (green) line is the foreskin's retracted inside fold, gathered behind the coronal sulcus.



4. The foreskin retracted farther. Almost the entire penile shaft is now covered with foreskin. The area between the upper (blue) line and the lower (green) line is the foreskin's retracted outside fold. The area between the lower (green) line and the glans is the foreskin's retracted inside fold. If the skin were released, it would return to its position in #3.



5. The foreskin retracted as far as it will comfortably go. The area between the lower (green) line (the only line now visible) and the glans is the foreskin's fully retracted inside fold. (One of the fingers holding the foreskin back is partially visible.) The entire penile shaft is now covered with foreskin. Well over half of the shaft is covered with the foreskin's retracted inside fold. Veins, arteries, capillaries, and smooth glans texture clearly visible.

These five photographs are the last five photographs of *33 Photographs of the Intact Adult Male Foreskin*, exhibited at the Third International Symposium on Circumcision at the University of Maryland, May 22-25, 1994. They have been printed in *Awakenings: A Preliminary Poll of Circumcised Men (Revealing the Long-Term Harm and Healing the Wounds of Infant Circumcision)* (NOHARMM, 1994); the November 1995 issue of the Montreal newspaper, *Le Presse*; *Sexual Mutilations: A Human Tragedy* (Proceedings of the Fourth International Symposium on Circumcision, Lausanne, Switzerland, August 9-11, 1996) (Plenum, 1997); and elsewhere. Attorney David Llewellyn (Atlanta Circumcision Information Center) told me they helped the jury arrive at its verdict in the successful wrongful circumcision lawsuit in Birmingham, Alabama, 1995, in which he was attorney for the plaintiff.

Permission to copy, print, reproduce, transfer, and distribute, in whole or in part, without profit, hereby granted